

# Rehabilitation of Phthisis Bulbi: A Case Report

PATIL BRAJESH A., MANKANI NIVEDITA H., CHOWDHARY RAMESH, E. NAGARAJ

## ABSTRACT

Maxillofacial prosthetics refers to all artificial prosthesis that restores missing parts of the face due to trauma, a congenital anomaly or surgically removed, the reason being either malignant or benign neoplasia. The objective of this article is to reveal the final rehabilitation of uniocular phthisis bulbi, a clinical case treated with a scleral cover shell in a male patient whose cause

of defect was trauma. These prosthesis are the most difficult to perform, with good results, because they try to reconstruct a mobile organ with a non-mobile prosthesis. Maxillofacial prosthesis increases the patient's quality of life and helps enhance their confidence. Patients who have been rehabilitated in such a way are ready to be integrated again in society.

**Key Words:** Orbital prostheses, Ocular prostheses, Phthisis bulbi, Scleral cover shell

## INTRODUCTION

Eyes are generally the first features of the face to be noted [1]. An unfortunate loss or absence of an eye may be caused by a congenital defect, irreparable trauma, tumour, painful blind eye, sympathetic ophthalmia or the need for histological confirmation of a suspected diagnosis [2]. The disfigurement associated with the loss of an eye can cause significant physical, psychological and emotional problems [3]. Most patients experience significant stress, primarily due to adjusting to the functional disability caused by the loss and to societal reactions to the facial impairment. Replacement of the lost eye as soon as possible is necessary to promote physical and psychological healing for the patient and to improve social acceptance [4]. A fundamental objective when restoring an anophthalmic socket with an ocular prosthesis is to enable the patient to cope better with the difficult process of rehabilitation [5]. A multi-disciplinary management and team approach are essential in providing accurate and effective rehabilitation and follow-up care for the patient. Therefore, the combined efforts of the ophthalmologist, the plastic surgeon and the maxillofacial prosthodontist are essential to provide a satisfactory ocular prosthesis [6]. Ocular prostheses are either ready-made or custom-made. Prosthetic rehabilitation of a patient is greatly enhanced if an implant is placed in the orbit [7].

Maxillofacial Prosthodontics is an art and science, which provides life-like appearance to the missing structures of an individual. The role of the maxillofacial prosthodontist in fabricating an ocular prosthesis with acceptable esthetics, to restore facial symmetry and normal appearance for the anophthalmic patient becomes essential [4].

A case report of a patient with uniocular phthisis bulbi, rehabilitated by a custom made scleral cover shell prosthesis is presented.

## CLINICAL REPORT

A 35-year-old male presented with the chief complaint of blindness associated with the decreased size of the right eye [Table/Fig-1]. On clinical examination, it was found that the cause of the defect

was trauma (needle prick) occurred at the age of 4 years. Due to the poor socio-economic status and illiteracy, no proper care was taken, thus leading to the present clinical situation.

On palpation it was found that, there was no associated pain, discomfort or residual edema. Thorough ophthalmic evaluation was done and it was diagnosed as Phthisis bulbi [Table/Fig-2].

The appropriate treatment was planned and was decided to fabricate a custom made scleral cover shell. The whole procedure regarding the fabrication of the prosthesis including its maintenance and limitations were explained to the patient. Impression of the external surface of the defective eye was made with high viscosity polyvinyl siloxane (Reposil, Dentsply, Germany). The impression was invested with dental plaster (Type II, Goldstone, Asian chemicals, Gujarat, India) to obtain the cast. Spacer was adapted and custom tray fabricated using self-cure clear acrylic resin (DPI RR cold cure; Bombay Burma Trading corp. Ltd). To attach a syringe for injecting impression material, a 2-3 mm diameter perforation was made around approximately at pupil location. Multiple perforations of 1-2 mm were made over the remainder of the surface, which sufficed for the retention of the impression material. The custom tray was trimmed, polished and disinfected. It was tried in the patient to check for extension and proper orientation. The tray was placed in the socket and the syringe was loaded with low viscosity polyvinyl siloxane (Reposil, type II, Dentsply, Germany). The impression material was injected into the tray and patient was instructed to perform all the movements of the eye, so that the functional impression was recorded [Table/Fig-3]. After removal from the socket, the impression was checked for acceptability. After beading and boxing [Table/Fig-4], the impression was invested with die stone (type IV). Wax pattern conformer was then carved and contoured to give it the simulation of the lost eye.

Try-in was done with the wax conformer to assess the fit, contour, comfort, size, support from the tissues, and the simulation of eye movement in comparison with natural eye. Using lost wax technique, the scleral cover shell was fabricated using heat cured

tooth colored acrylic resin (DPI, Dental products of India, Mumbai); the shade was selected using shade guide in comparison with adjacent natural eye sclera. Try-in of the scleral shell was done to check proper fit and contour. With the help of anatomical landmarks, and that of the adjacent natural eye the position of the iris was determined [Table/Fig-5]. On a custom-made iris disc, the color of the patient's iris was replicated by painting. Later, a custom made corneal button was glued over the painted iris disc [Table/Fig-6]. The scleral tone and vascularization was simulated by tinting and applying artificial veins in order to achieve desired scleral replication.

A thin layer of clear acrylic resin was added over the painted iris and sclera, which brings the depth and magnifies the detail of the iris. After polymerization, the prosthesis was finished and polished. Disinfection of prosthesis was done with 0.5% chlorhexidine and 70% isopropyl alcohol for 5 mins, later the prosthesis was rinsed in sterile saline solution and inserted [Table/Fig-7]. Instructions were given to the patient regarding proper care and hygiene maintenance techniques in order to facilitate successful adaptation of the prosthesis. Also instructions of the use of ancillary products (e.g., lubricants, lubricant delivery systems, cleansers.) and procedures were given in order to help the patient adapt to the prosthesis.

**DISCUSSION**

Man has known the art of making artificial eyes from the days of the early Egyptians and the Peruvian Indians, but not until World War II, and the development of refined plastics has been the option for a satisfactory aesthetic ocular prosthesis [8].

Replacement of any anatomic structure by artificial means remains a challenge, especially in the facial region. The replacement must be one, which blends with the adjacent tissues as well as replaces the missing structures. Careful planning and meticulous attention

in detail fabrication of prosthesis can enable the maxillofacial prosthodontist to make a major contribution in the rehabilitation of the patient with an orbital defect [9].

Empirically fitting a stock eye, modifying a stock eye by taking an impression of the ocular defect and the custom eye technique are the most commonly used techniques. However many optical companies developed the mass-produced stock acrylic resin prosthesis. Though the fabricating procedure is rapid, but the results are not entirely satisfactory. They even have a limited choice of sizes and iris color matching.

Custom made, hand painted, and individually constructed acrylic resin artificial eye have been proved to be the most satisfactory ocular replacement. The fabrication of a custom made acrylic resin eye provides a more precise and satisfactory aesthetic as an impression outlines the defect contents, with the iris and the sclera being fabricated and painted individually with ocular defect. Advantages include improved adaptation to underlying tissues, increased mobility of the prosthesis, improved facial contours, and enhanced esthetics gained from control over the size of the iris and pupil and color of the iris and sclera [10].

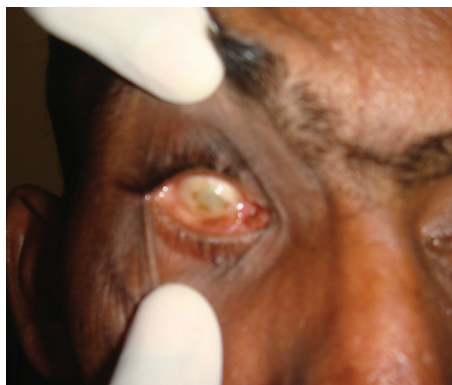The ocular prostheses are either ready-made or custom-made and are produced from either glass or methyl methacrylate resin. Glass is not the material of choice as it is subject to damage and surface deterioration from contact with orbital fluids, leading to a usable life expectancy of only 18–24 months [11].

Methyl methacrylate resin is superior to other ocular prosthetic materials with regard to tissue compatibility, aesthetic compatibilities, durability and permanence of colour, adaptability of form, cost and availability [12].

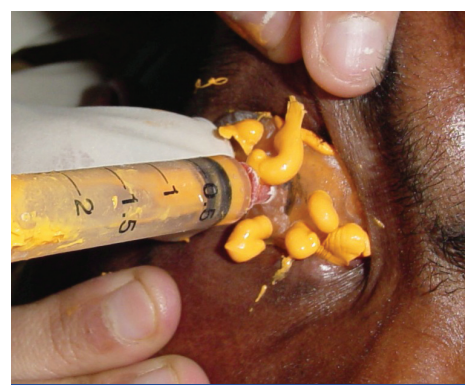The United States Navy is credited with the development of custom acrylic resin ocular prostheses [12].After conducting



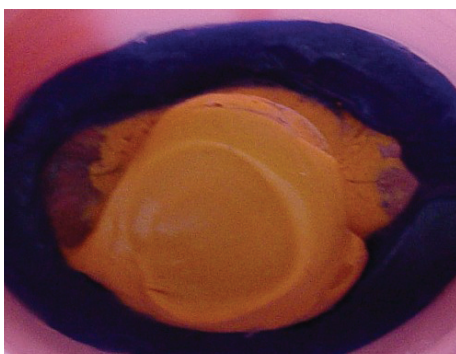[Table/Fig-1]: Pre-prosthetic



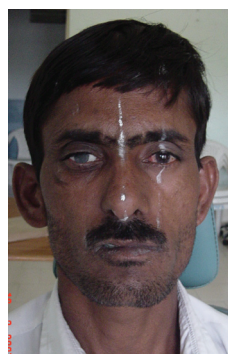
[Table/Fig-2]: Defective right eye



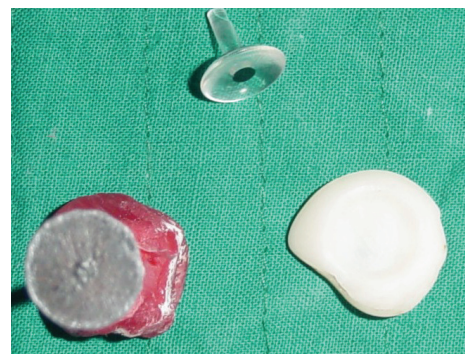
[Table/Fig-3]: Impression of the defective eye



[Table/Fig-4]: Beading and boxing of the final impression



[Table/Fig-5]: Try in of the scleral shell



[Table/Fig-6]: Customized iris disc with corneal button

extensive research into various aspects of ocular prosthesis fabrication. Navy investigators concluded that each enucleated eye socket was individual in nature. Hence, it is critical to make an accurate impression of the site to be restored. Criteria for an acceptable impression included accurately recording the posterior wall, the position of the palpebrae in relation to the posterior wall, and the greatest extent of the superior and inferior fornices of the palpebrae.



**[Table/Fig-6]:** Final prosthesis in situ

## CONCLUSION

The major advantages of a custom made ocular prosthesis are improved fit, mobility, and esthetics. Disadvantages include increased fabrication time and cost. A critical fabrication step involves the impression of the socket. Numerous impression methods exist. Effectiveness and desirability of impression methods depend to a large degree on operator experience and materials and equipment available.

## REFERENCES

- [1] Doshi PJ, Aruna B. Prosthetic Management of patient with ocular defect. *J Ind Prosthodont Soc* 2005; 5: 37-38.
- [2] Raflo GT. Enucleation and evisceration. In: Tasmun W, Jaeger E eds. *Duane's Clinical Ophthalmology*, Revised edn, Vol. 5. Philadelphia: Lippincott-Raven, 1995: 1-25.
- [3] Lubkin V, Sloan S. Enucleation and psychic trauma *Adv Ophthalmic Plast Reconstr Surg* 1990; 8: 259-62.
- [4] Artopoulos II, Montgomery PC, Wesley PJ, Lemon JC. Digital imaging in the fabrication of ocular prostheses. *J Prosthet Dent* 2006; 95: 327-30.
- [5] Ow RKK, Amrith S. Ocular prosthetics: use of a tissue conditioner material to modify a stock ocular prosthesis. *J Prosthet Dent* 1997; 78: 218-22.
- [6] Bartlett SO, Moore DJ. Ocular prosthesis: a physiologic system. *J Prosthet Dent* 1973; 29: 450-59
- [7] Erpf SF. Comparative features of plastic and/or glass in artificial-eye construction. *Arch Ophthalmol* 1953; 50: 737
- [8] Welden RB, Niiranen JV. Ocular prosthesis. *J Prosthet Dent* 1956; 6: 272-78.
- [9] Guerra LR, Finger IM, Echeverri J, Shipman B. Impression making, sculpting, and coloring of orbital prostheses. *Adv Ophthalmic Plast Reconstr Surg*. 1992; 9:287-96.
- [10] Mark F. Mathews, DDS, MS, 1 Rick M. Smith, DDS, MS, 2 Alan J. Sutton, et al. The Ocular Impression: A Review of the Literature and Presentation of an Alternate Technique. *J Prosthodont* 2000; 9:210-16.
- [11] Erpf SF. Comparative features of plastic and/or glass in artificial-eye construction. *Arch Ophthalmol* 1953; 50: 737.
- [12] Cain JR. Custom ocular prosthetics. *J Prosthet Dent* 1982; 48: 690-94.
- [13] Beumer J III, Curtis TA, Firtell DN eds. *Maxillofacial Rehabilitation: Prosthodontic and Surgical Considerations*. St Louis: CV Mosby, 1979: 352-62.
- [14] Smith B, Valauri AJ. The orbit: Anophthalmos and microphthalmos. In: *Converse J Med. Reconstructive Plastic Surgery*, Vol. 2. Facial Injuries: the Orbit, the Nose, the Cranium. Philadelphia: WB Saunders, 1977: 962-68.

### AUTHOR(S):

1. Dr. Patil Brajesh A.
2. Dr. Mankani Nivedita H.
3. Dr. Chowdhary Ramesh
4. Dr. E.Nagaraj

### PARTICULARS OF CONTRIBUTORS

1. MS, Associate Professor, Department of Ophthalmology, S. Nigalingappa Medical College, Hanagal Shri Kumareshwar Hospital and Research Centre, Bagalkot, Karnataka, India.
2. MDS, Assistant Professor, Department of Prosthodontics, PMNM Dental College and Hospital, Bagalkot 587101, Karnataka, India
3. MDS, Professor, Department of Prosthodontics, HKE's SN Dental College and Research Centre, Gulbarga, Karnataka, India
4. MDS, Assistant Professor, Department of Prosthodontics, PMNM Dental College and Hospital, Bagalkot 587101, Karnataka, India

### NAME, ADDRESS, TELEPHONE, E-MAIL ID OF THE CORRESPONDING AUTHOR:

Dr. Nivedita H. Mankani, Assistant Professor,  
Department of Prosthodontics,  
PMNM Dental College and Hospital,  
Bagalkot - 587101, Karnataka, India.  
Phone: +919481212040  
E-mail: drniveditam@yahoo.co.in

### DECLARATION ON COMPETING INTERESTS:

No competing Interests.

Date of Submission: **Aug 18, 2011**  
Date of peer review: **Oct 30, 2011**  
Date of acceptance: **Nov 24, 2011**  
Date of Publishing: **Dec 25, 2011**